

CASE STUDY

Improved Hearing Following Chiropractic in a 10-Year-Old Child with a History of Chronic Otitis Media & Hearing Loss: A Case Study & Review of the Literature

Parker Adams, DC¹ & Erica Kiela, DC²

Abstract

Objective: To describe the use of the Gonstead Technique in the management of a child with symptoms of otitis media with effusion, including conductive hearing loss and feelings of ear pressure.

Clinical Features: The 10-year-old female had a history of ear infections as an infant, and serous otitis media with hearing loss when 5 years of age for which she had undergone bilateral myringotomies with tubal placement. Complaints of hearing difficulties of one-year duration at time of presentation to the chiropractic office. Pure tone audiometry showed a mild hearing loss.

Intervention and Outcomes: Adjustments of vertebral subluxations using Gonstead Technique resulted in normalized audiology testing, elimination of ear discomfort, and sustained hearing ability.

Conclusions: The successful chiropractic care of a child with hearing loss associated with otitis media is described. Research has shown a relationship between otitis media, eustachian tube dysfunction, and vertebral subluxation. This study provides supporting evidence that children with similar complaints may benefit from chiropractic care.

Key words: *Chiropractic, otitis media, effusion, hearing loss, Gonstead, vertebral subluxation, tympanostomy, eustachian tube, adjustment, spinal manipulation*

Introduction

Otitis media with effusion, also called serous otitis media, is one of the most common diagnoses of children.¹⁻⁴ Approximately 90% of children have otitis media with effusion (OME) at some time before school age, and there are about 2.2 million diagnoses of OME every year in the United States, which costs the economy \$4.0 billion.² OME is characterized by fluid in the middle ear in the absence acute signs and symptoms of ear infection.^{1,5}

This ear fluid can lead to decreased mobility of the tympanic membrane, resulting in conductive hearing loss.^{1,2} Cases of OME can be easy to miss, as there is generally no ear pain, but instead may present as hearing loss, ear fullness, or difficulty performing in school. OME can be asymptomatic as well.^{1-3,5}

Acute otitis media (AOM) is more easily recognizable because of its rapid onset, ear pain, and red, bulging tympanic membrane.² More than half of OME cases are preceded by acute otitis media, which is the most common infectious disease in childhood.⁵ There is concern among the healthcare community over the potential long-term developmental consequences of OME including delayed or impaired speech and behavioral issues.^{2,4,6}

Risk factors for otitis media with effusion involve both intrinsic and extrinsic factors. Intrinsic risk factors include low gestational age, lower birth weight, lack of breastfeeding, previous ear infection or history of AOM, hearing loss, mouth breathing or snoring, the common cold, and recurrent upper

1. Private Practice of Chiropractic, Roanoke, VA
2. Private Practice of Chiropractic, Plymouth, WI

respiratory infections. Extrinsic risk factors are attending day-care, higher number of siblings, and the winter season.^{1,3,6} Zielhuis et al. defined two peaks of age for prevalence: one around 2 years old and the other at 5 years old. Relative risk for OME decreases with increasing age.^{1,5}

Eustachian tube dysfunction and an immature immune system are possible etiologies of OME.¹ The eustachian tube connects the middle ear to the pharynx. Dilation of the tube by the tensor veli palatini muscle allows for equalization of air pressure and fluid drainage.⁷ The anatomical differences in the eustachian tube in adults as compared to children make children more susceptible to ear infections. The eustachian tube in children is more horizontal, shorter and wider than adult anatomy.⁸ Chronic obstruction of the eustachian tube due to faulty dilation causes a secondary reaction of inflammation of the middle ear mucosa. The most common bacteria involved in AOM are *S. pneumonia*, *H. influenzae*, and *M. catarrhalis*, but the role of these bacteria in OME pathogenesis remains unclear.⁵

Allopathic Management

Diagnosis of suspected OME is achieved by pneumatic otoscopy and tympanometry. Despite recommended guidelines, only about 20% of primary care physicians are using pneumatic otoscopy.² Considering the relatively asymptomatic nature of OME, the low percentage of diagnostic procedures performed is cause for concern.

Traditional options for allopathic treatment of OME include myringotomy and aspiration of the effusion, tympanostomy or ventilation tube insertion, and steroids. Steroids can be administered directly via intratympanic injection, or systemically with a nasal spray, although nasal sprays have been shown to be ineffective on middle ear fluid.^{2,9} Guidelines from the American Academy of Otolaryngology updated in February 2016 advise a more conservative approach to treating OME.² These guidelines recommend avoiding antibiotics, steroids, antihistamines, decongestants, or nasal steroid sprays unless under exceptional circumstances. Less invasive treatments from the medical community are stressed because “about 30% still do treat with antibiotics, despite recommendations in 2004 against the practice”.²

There is encouragement of a watch and wait approach to doctors in the allopathic field regarding OME; however, tympanostomy, surgical tube insertion in the tympanic membrane, is still recommended in cases of OME persisting for more than 3 months in order to restore hearing.² Adverse risks of tympanostomy include tube otorrhea, occurring in 29-64% of cases, tympanosclerosis, and tympanic membrane perforation.^{4,9} About 1 in 4 children get an ear infection after tube insertion, and the same number of children will need to get the tubes replaced.²

The high cost and morbidity associated with OME combined with the call for a more conservative approach indicates a need for effective alternative therapies. For parents seeking alternatives to the traditional allopathic medical model, chiropractic emerges as a popular option. In a report from the Centers for Disease Control and Prevention, chiropractors

were the most common complementary and alternative medicine provider visited by pediatrics.¹⁰ A survey of Canadian chiropractors revealed that otitis media was one of the most common reasons to seek out chiropractic care for patients 10 years old or younger.¹⁰

The purpose of this study is to report on the case of a 10-year-old female with symptoms of OME, including conductive hearing loss and feelings of ear pressure, who presented to a chiropractic office specializing in the Gonstead Technique. She had a prior history of serous otitis media and hearing loss for which she had undergone bilateral myringotomies with tubal placement. A discussion of the chiropractic literature and proposed mechanism of the role of vertebral subluxation in conductive hearing loss associated with otitis media will follow.

Case Report

History

A 10-year-old Caucasian female began care at a chiropractic office with complaints of hearing difficulty and feelings of ear pressure that had been occurring for over a year. The patient had a past history of ear infections as an infant for which antibiotic were administered. When the girl was 5 years old, her parents sought care from an otolaryngologist after failing a hearing screening performed at school. She was diagnosed with conductive hearing loss due to eustachian tube dysfunction and serous otitis media. The patient underwent bilateral myringotomies and tube placement. Two weeks following surgery, the audiogram showed restored hearing (Figures 1 & 2). Five years later the patient began to experience hearing difficulties again and returned to her otolaryngologist.

Within a 6-month period she failed two out of three audiological evaluations (Figures 3-5).

The patient’s hearing was evaluated using conventional audiometry and charted as pure tone average (PTA), speech reception threshold (SRT) and word recognition or discrimination (DISCRIM). Conventional audiometry can be used to test the hearing of children aged 4 years and older. The test is done in a quiet room with the patient wearing earphones and raising a hand to indicate when a sound is heard.

Each ear is tested over a range of frequencies from at least 500 to 4000 Hertz (Hz).¹¹ The hearing thresholds at each frequency level are averaged as the PTA. The SRT is the softest intensity a two-syllable word can be heard then repeated by the patient. The SRT should be within 5 dB of the PTA.¹² Mild hearing loss is described as a PTA between 20 and 40 decibels (dB), moderate as 40 to 70 dB, and severe as 70 to 95 dB.¹¹ The third audiogram (Figure 5) showed a PTA of 33 dB and 25 dB for the right and left ear, respectively.

Nine days after she failed this third hearing test, the patient’s parents brought her in for a chiropractic evaluation. Along with hearing loss, the patient described problems with ear infections and feelings of pressure. Although the patient did not have a medical diagnosis at this time, the focus of this

report is OME considering the past diagnosis of serous otitis media and symptoms consistent with those of OME.

Physical Examination

General observations revealed a somewhat overweight ten-year-old girl who was lucid, cooperative, and able to ambulate freely. Blood pressure in the right arm was 113/63 mmHg. Active ranges of motion of the spine were evaluated. The patient experienced localized neck pain upon cervical flexion and back pain upon thoracolumbar extension. Deep tendon reflexes were hypoactive bilaterally in both the upper and lower extremities. Dermatome testing was normal bilaterally in both the upper and lower extremities. Toe walk and heel walk was performed without difficulty.

Chiropractic Exam according to the Gonstead Technique

A thorough chiropractic examination of the spine was performed in order to assess for vertebral subluxation. The examination for subluxation utilized criteria from the Gonstead Technique including visualization of the patient's back, thermography, and static and motion palpation of the spinal joints.¹³

During visualization, the doctor is inspecting the patient's back, looking for any abnormal skin marks, acne, scars, and muscular or postural asymmetries. Visualization encompasses inspection for intersegmental and global asymmetries, in both static positions and dynamic movements.¹³

Thermography is used by chiropractors to assess function and any aberrations in the autonomic nervous system.¹⁴ Since the sympathetic nervous system shunts blood via vasoconstriction and dilation of blood vessels, it is thought that differences in skin temperature from side-to-side indicate autonomic nervous system imbalance.¹⁵ The thermography was done with a Nervoscope, a dual-probed microvoltmeter used to detect differences in paraspinal skin temperature, manufactured by Electronic Development Labs, Inc. (EDL)^{16, 17} Heat readings are demonstrated by a meter needle.

A sudden deviation in temperature within one spinal level demonstrated by a quick flick of the meter needle is called a "break". This "break" is considered to indicate autonomic dysfunction.¹³⁻¹⁵ A study on the reliability of the Nervoscope revealed good intra and interexaminer reliability during dynamic scanning in the thoracic region; however, this reliability was not present in the cervical region.¹³ There is an overall scarcity of research regarding the reliability or validity of the Nervoscope.¹⁵ The Nervoscope had a compliance issue with the Food and Drug Administration (FDA) regarding medical device reporting in 2014.¹⁸ Corrective actions were made by EDL, Inc. and as of June 2015, the Nervoscope sustains compliance with the FDA.¹⁹

Palpation is done with a skin-on-skin contact using the digital pads of the hands, detecting trophic changes at intersegmental vertebral levels. A subluxated vertebral motion segment is in a damaged, inflammatory state, resulting in a localized pooling of fluid or edema in the subcutaneous tissues surrounding the spinous process.¹³ This edematous region may be tender upon palpation. The patient is also palpated along the paraspinal

muscles, assessing for variations in resting muscular tone. Motion palpation is done passively, with the chiropractor moving the patient through flexion, extension, lateral bending, and rotation. The chiropractor uses a light fingertip touch to assess the motion of a vertebral segment in each of these planes of motion, comparing the quality and amount of motion to the segment directly inferior.^{13,16}

On this initial evaluation, the Nervoscope showed breaks at C1, C7, and L5. On subsequent visits, breaks were also found in the mid-thoracic and sacral regions. Digital palpation at the levels of the breaks revealed slight edematous findings and point tenderness. Motion palpation revealed intersegmental fixation at these same levels.

In order to further evaluate these spinal subluxations, full-spine weight bearing AP and lateral radiographs were taken (Figure 7). On the x-ray films, the right ilium was internally rotated 6 mm about the Y-axis and anteriorly and superiorly rotated 2 mm about the X-axis with respect to the opposite ilium. The sacral base was posteriorly rotated 3 mm on the right (-θY). Radiographic analysis of C1 as compared to C2 showed an anterior and superiorly angled anterior tubercle, and a superior transverse process on the right. C1 was given the Gonstead listing of ASR(-θX, -θZ). The L5 spinous process was found to be rotated to the left as compared to the S1 tubercle. Because of this left spinous rotation and the extension malposition as found on motion palpation, L5 was given the listing PL(-Z, -θY). The spinous process of C7 showed a similar rotation and was also given the listing PL

Diagnosis on the first visit included subluxation cervical region and subluxation lumbar region. Diagnosis over the course of treatment also included subluxation of thoracic and sacral regions.

Intervention

Over the course of one year, the patient was seen 31 times for evaluation and chiropractic adjustments for vertebral subluxation. She was initially seen once per week for 18 weeks, then frequency was reduced to one visit every two weeks for 6 weeks. She was seen once or twice per month for the remaining 28 weeks. Subluxations were found at various segmental levels over the course of treatment. The most common areas of subluxation were at L5, C1, C7, T3 and S2 sacral segment. Other subluxations were found at C2, T1, T5, T6, T7, T9, L1, and the sacral base (Table 1). Depending on the chiropractic examination findings, the patient had between one and three adjustments per visit. The patient was adjusted by a high-velocity, low-amplitude (HVLA) thrust in a specific line of correction, pertaining to the direction of the misalignment and the orientation of the vertebral disc plane line. In this case of a pediatric patient, special care was taken in regards to limiting depth of thrust.

Atlas, C2, C7, and T1 were adjusted with the patient in a seated position in the Gonstead cervical chair. In the cervical chair adjustment, the doctor stands behind the patient, taking a fingertip contact on the spinous process or lamina of the involved vertebrae, and delivers an HLVA thrust in a posterior to anterior direction (+Z). The patient's head and neck are stabilized in this position by the chiropractor's non-adjusting

hand.²⁰ To adjust C1 in this seated position, the chiropractor contacts the anterolateral portion of the atlas transverse process of the side of superiority relative to axis. The contact is taken with the distal thumb pad and the patient's head laterally flexed over the contact side. The HLVA thrust is lateral to medial with an inferior arching motion.²¹ Thoracic and upper lumbar segments were adjusted with the patient in a prone position, the chiropractor using a pisiform contact on the involved spinous process or transverse process. The adjustive thrust was primarily anterior. L5 and sacral segments were adjusted with the patient in a side-lying position with their top knee bent and bottom knee straight. The doctor used either a pisiform or fingertip contact on the spinous process or sacral tubercle involved. Because the patient had unfused sacral segments, the individual segments were adjusted separately, as opposed to one sacral bone.

Each vertebral segment has the potential to misalign in a specific direction as determined by both palpation and radiographic analysis. A Gonstead listing designates that direction of misalignment.¹⁶ The segments most frequently adjusted and their listings were the following: L5 (PL), C1 (ASR), C7 (PL), T3 (PL), and S2 (P).

During the course of care, the chiropractor also suggested to the mother that the patient reduce her dairy intake and take a quality probiotic supplement or eat cultured, fermented foods.

Outcomes

The patient received chiropractic adjustments according to the Gonstead Technique for 31 visits over the course of one year. After the first adjustment, the patient started crying and claimed the adjustments were painful. At the second visit one week later, the patient did not have the same emotional or painful response to the adjustment.

By the sixth visit, the mother reported she thought her daughter's hearing was improving. Within a week after the sixth visit, they went back to the otolaryngologist to have another hearing test. This audiogram showed normal hearing with a PTA of 12 dB and 10 dB in the right and left ears, respectively (Figure 6). The patient also had perceptively less fluid in her ears at this time. The patient continued the chiropractic care, and at a checkup with the child's pediatrician (after visit number 20) the doctor told the mother her daughter was doing well, with one ear completely clear and the other containing a small amount of fluid.

Prior to starting care at the chiropractic office, the patient would experience colds which would typically result in hearing loss and a sense of fullness in the ear. Over the course of chiropractic care, the post-coryzal hearing difficulty would not occur. The patient continued to experience longer periods of time without hearing problems or ear difficulties. As her chiropractic care frequency was reduced, her hearing remained intact. One year after the start of care the patient was moved to a wellness schedule of one visit every 4 to 6 weeks. Nine months after beginning wellness care, the patient was still in good health with zero complaints of hearing difficulties.

Discussion

Review of Literature

A search of the peer-reviewed literature pertaining to chiropractic and hearing difficulties associated with otitis media was conducted by utilizing the databases Index to Chiropractic Literature and McCoy Press, in addition to a hand-search of references in other articles. Searches of the keywords "otitis media effusion" and "otitis media" resulted in several relevant articles, but only six of these studies included cases with descriptions of hearing difficulties as well as ear infections. Because doctors of osteopathy as well as chiropractors consider manipulation of the spine to have musculoskeletal and non-musculoskeletal effects, literature involving either chiropractic intervention or osteopathic manipulative therapy (OMT) was included. Most of the studies in the chiropractic and osteopathic literature tend to focus on acute otitis media, instead of otitis media with effusion.²²

The literature of otitis media presented in this discussion consists of fourteen case studies, four case series, and four randomized clinical trials (RCT). These articles are listed in Table 2. Manual therapy interventions included various chiropractic techniques, cranial adjustments, OMT, and soft tissue effleurage of the sternocleidomastoid muscles. The age range of the patients was from 6 months to 9 years old. The case studies all showed favorable results of chiropractic in children with AOM, OME, recurrent otitis media, or nondescript ear infection.^{3,8,23-34} Many of the studies reported avoidance of ventilation tube surgery.^{3,25,27,30,32-34}

The four case series reported outcomes of chiropractic and OMT in cohorts with 315, 8, 46, and 21 subjects in each study, respectively.^{7,35-37} Fallon monitored outcomes with tympanography and otoscopic exam.⁷ Zhang focused on AOM and utilized an oral thermometer to track body temperature.³⁷ There were four examples of randomized clinical trials.^{4,38-40} The OMT treatment group in the study by Mills et al. showed fewer episodes of AOM, fewer surgical interventions, and more normal tympanograms.³⁸ Wahl et al.'s clinical trial resulted in no significant difference in otitis media episodes between the OMT and sham groups.⁴⁰ In 2014, Steele et al. showed a significant improvement in middle ear effusion in children receiving OMT as compared to standard care alone.³⁹ The one chiropractic clinical trial involving otitis media was published in 1999. The purpose of this study was to assess the feasibility of a full scale RCT, and therefore did not report on clinically meaningful improvement following chiropractic care.⁴

Chiropractic Management of Hearing Loss associated with Otitis Media

Of the 22 articles included in this discussion, six of the studies specifically mention subjects with hearing loss or OME.^{3,23,25,30,31,38}

All but one of the articles pertaining to hearing loss associated with otitis media or OME were case studies. The studies all found good results of improved hearing in children with otitis media after chiropractic treatment; however, the results of

these studies should be understood cautiously due to their small sample size and lack of control groups.

In 2004, O'Connor found diversified chiropractic care resulted in 95% restoration of hearing in a 9-year-old girl.³⁰ The girl had been under chiropractic care for 3 weeks when the otolaryngologist cancelled the tympanostomy tube surgery, declaring the tubes unnecessary. Unfortunately, there were no audiograms or other documentation from the patient's medical doctor provided.³⁰

A 2011 case study by Dwyer & Boysen on a 6-year-old male with conductive hearing loss and previous myringotomy included audiograms pre and post chiropractic treatment.²⁵ Six chiropractic adjustments of the spine and cranium over 22 days resulted in an audiogram showing normalized hearing and a clear reduction in the air-bone gap. The patient also avoided a repeat tube insertion as initially recommended by his ENT prior to chiropractic care. Chiropractic techniques utilized in this patient included diversified, Gonstead, Sacro-Occipital Technique, and Applied Kinesiology craniopathy.²⁵

A 2011 case study of a 4-year-old male showed improved hearing after chiropractic treatment involving the use of diversified manual techniques and instruments.³¹ The patient originally presented with complaints of bilateral hearing loss and OME, as well as speech difficulties and behavioral concerns. The audiogram before chiropractic care showed an abnormal SRT and decibel reading at 500 Hz for both ears. After 11 visits, audiometry demonstrated hearing within the normal decibel range; however, the SRT remained unchanged.³¹

Brown documented a case study on a 3-year-old female brought in for chiropractic evaluation with a history of three unsuccessful tympanostomy tube implantations.²³ The third set of tympanostomy tubes required removal due to complications of excessive fluid accumulation, tympanic membrane rupture, speech disturbances, and bilateral hearing loss. The initial care plan was set at five visits per week for three weeks utilizing diversified technique. After seven visits the patient reported "I can hear again". The audiology report after 14 chiropractic visits showed a normalized speech audiometry (SRT of 15 dB bilaterally), improved from 30 dB in the right ear and 20 dB in the left ear. A follow up visit with the patient's pediatrician revealed diminished middle ear effusion.²³

Saunders reported on a 3-year-old male who presented with odorous discharge from both ears that had been occurring continuously for 10 months after an ear infection. The child had an 18-month history of ear infections and a slight hearing deficit. The patient had many risk factors for otitis media with effusion including a lower gestational age, lower birth weight, and no breastfeeding.³ The child received diversified adjustments to the cervical spine and the use of an Activator in the thoracic region. Discharge ceased after first chiropractic visit. A hearing test 3 months after the end of chiropractic treatments showed improved hearing. At 6 years of age, the patient had no further ear infections or difficulties with hearing.³ This study failed to provide an audiogram or other medical documentation.³

The clinical trial by Mills et al. utilized audiologic evaluations

as part of the objective data collection.³⁸ Fifty-seven patients aged 6 months to 6 years with recurrent otitis media were randomly placed into a group receiving OMT intervention or a control group. Hearing ability of the patients was not specified, although all subjects did receive audiologic evaluations. There was no significant difference between the control group and intervention group in regards to pre and post audiograms. There were fewer episodes of AOM, fewer surgical interventions, more normal tympanograms and no adverse reactions reported for the OMT intervention group.³⁸

The Vertebral Subluxation Complex

Several theories of subluxation exist in the literature; this discussion will focus on fixation dysfunction via the dysafferentation model. The vertebral subluxation complex (VSC) is a pathophysiologic process of joint dysfunction resulting in aberrant neurological function. The functional spinal unit (FSU) allows normal biomechanical movement in the three planes of motion around the facet joints and intervertebral disc. The FSU is composed of two adjacent vertebrae, the intervertebral disc, and the ligaments connecting the structures.⁴¹ Surrounding these articulations and ligaments are several nociceptive and mechanoreceptive structures.⁴²

The intervertebral disc is an important structure for normal spinal biomechanics.⁴¹ Its two constituents, the annulus fibrosus and nucleus pulposus, create ideal weight bearing properties and allow vertebral motion in the six degrees of freedom. Due to either macrotrauma or microtrauma, small fissures form in the annulus, allowing extrusion of a part of the nucleus away from the annulus. The disruption of the nuclear/annular relationship results in interference of normal spinal motion. This damage to the disc is termed disc derangement, and is one possible mechanism for the etiology of fixation dysfunction of the FSU.^{41,43} Vertebral joints without a disc, such as the atlanto-axial articulation, can become fixated in an inflammatory state as the synovial joint capsule swells with edematous fluid.^{41,43}

Disc derangement in a pediatric case can result from the physical stresses attributed to slips and falls sustained as the child learns how to crawl and walk, or prolonged sitting posture while in school or watching a screen. Inflammation occurs in the body from chemical as well as physical stresses.⁴⁴ In this case study, chemical stresses to the subject can be understood as her dietary intake of dairy and multiple rounds of antibiotics. These various causes of stress to the body have the potential to cause disc derangement or begin an inflammatory process in the atlanto-axial articulation.

The fixation dysfunction manifests as dyskinesia. The sinuvertebral nerve, which innervates the intervertebral disc, as well as mechanoreceptors and nociceptors surrounding the FSU transmit dysfunctional afferent signals to the dorsal horn of the spinal cord due to this dyskinesia. This alteration of afferent input to the central nervous system (CNS) results in a further alteration in efferent output, or dysponesis.⁴² More specifically, the increase of afferent stimulation of the posterior horn via the sinuvertebral nerve causes a spill-over effect into the nearby anterolateral horns. Dysautonomia can result from this spill-over, since the sympathetic nervous system resides in the lateral horn. One of the manifestations of

dysautonomia is differentials in bilateral skin temperature, as detected by paraspinal thermography. Abnormal muscular tone can also result from the spill-over, considering the anterior horn houses motor neurons.⁴²

The Role of the VSC in Conductive Hearing Loss of OME

As mentioned previously, eustachian tube dysfunction is a prevailing allopathic theory for the etiology of otitis media and middle ear effusion. The eustachian tube (ET) drains fluid from the middle ear. Without draining of this fluid, the motion of the tympanic membrane is inhibited, resulting in conductive hearing loss as seen in OME and this case report. The primary muscle responsible for opening the ET is the tensor veli palatini (TVP) muscle.⁷ The TVP muscle receives innervation from the medial pterygoid nerve, whose fibers originate from the mandibular branch of the trigeminal nerve. The muscle receives sympathetic fibers from C1-4 via the superior cervical ganglia, which also contains fibers from the trigeminal nerve.³⁰

Dyskinesia and distorted afferent information in the cervical spine will create disordered information within the integrating centers of the CNS, which results in compromised efferent information.⁴² The compromised output in this situation manifests as ET dysfunction due to disordered activation of the TVP muscle. Removal of fixation and restoration of normal biomechanics at the FSU level restores normal afferent input and subsequent efferent response. In this case, the normalization of output is the proper function of the TVP muscle. As the TVP muscle regains normal tone, dilation of the ET occurs, allowing drainage of fluids from the middle ear. Absence of fluid permits proper acoustic mechanics of the tympanic membrane, resulting in return of normal hearing.

Limitations of this study

Although this case report has shown positive results with chiropractic management of hearing loss associated with otitis media, this is a single case study lacking in methodological rigor. One cannot extrapolate results from a single case study to a larger population. Other interventions made in addition to chiropractic care included dietary recommendations and the addition of a probiotic supplement. Because of the favorable natural history of OME it is difficult to tell in this case whether the results were due to chiropractic intervention or time. There is a lack of control groups and presence of selection bias since this is a retrospective case report.

Conclusion

This case study describes the outcomes of chiropractic management of a 10-year-old girl with hearing loss and ear fullness with a prior history of ear infection, hearing loss, and bilateral myringotomies with tubal insertion. The chiropractic care focused on detection and reduction of vertebral subluxation according to the Gonstead technique. After six adjustments, an audiogram showed normalized hearing with a pure tone average within normal range. Over the course of a year, the patient showed continued improvements with ear fullness and retained hearing. Almost two years after starting chiropractic care, the patient maintains good health and no complaints of hearing difficulties. Limitations of this case

report include a small sample size, lack of a control group, and multiple variables.

The risk for speech and language delays associated with otitis media with effusion, combined with high morbidity is cause for concern. Considering that the clinical practice guidelines for medical doctors treating OME stress the importance of conservative treatments, chiropractic management should be considered as an effective alternative conservative option.

Most of the research on chiropractic and otitis media is low level research of case studies and case series. There are a few examples of randomized clinical trials (RCTs), with 3 out of the 4 examples being from the osteopathic literature, and only one on chiropractic.

The overall body of literature shows favorable results in regards to spinal manipulation and otitis media; however, when evaluating only RCTs and other high level research, the effectiveness of spinal treatments for otitis media is, at best, inconclusive.⁴⁵ High level research on efficacy of chiropractic care for all types of pediatric conditions is substantially lacking, especially considering parents continue to seek chiropractic care for their children.^{10,22,45} More randomized clinical trials with larger sample sizes, reliable outcome measures, and medical staff familiar with the tools for diagnosis of otitis media are recommended.

References

1. Martines F, Bentivegna D, Maira E, Sciacca V, Martines E. Risk factors for otitis media with effusion: Case-control study in Sicilian schoolchildren. *Int J Pediatr Otorhinolaryngol.* 2011;75:754-59.
2. Rosenfeld RM, Shin JJ, Schwartz SR, Coggins R, Gagnon L, Hackell JM, et al. Clinical practice guideline: otitis media with effusion executive summary (update). *Otolaryngol Head Neck Surg.* 2016;154(2):201-14.
3. Saunders L. Chiropractic treatment of otitis media with effusion: a case report and literature review of the epidemiological risk factors that predispose towards the condition and that influence the outcome of chiropractic treatment. *Clin Chiropr.* 2004 Mar;7:168-73.
4. Sawyer CE, Evans RA, Boline PD, Branson R, Spicer A. A feasibility study of chiropractic spinal manipulation versus sham spinal manipulation for chronic otitis media with effusion in children. *J Manipulative Physiol Ther.* 1999 Jun;22(5):292-8.
5. Minovi A, Dazert S. Disease of the middle ear in childhood. *GMS Curr Top Otorhinolaryngol Head Neck Surg.* 2014;13.
6. Engel J, Anteunis L, Volovics A, Hendriks J, Marres E. Risk factors of otitis media with effusion during infancy. *Int J Pediatr Otorhinolaryngol.* 1999;48:239-49.
7. Fallon JM. The role of the chiropractic adjustment in the care and treatment of 332 children with otitis media. *J Clin Chiropr Pediatr.* 1997;2(1):167-83.
8. Dunn-Sigouin K. Resolution of recurrent acute otitis media in a child undergoing chiropractic care: a case report. *J Clin Chiropr Pediatr.* 2015 Oct;15(1):1203-6.
9. Amer HS, El-Anwar MW, Elfeky AE. The efficacy of adjuvant intratympanic steroid treatment for otitis media with effusion in children. *Int Arch Otorhinolaryngol.* 2016;20:244-7.

10. Gleberzon BJ, Arts J, Mei A, McManus EL. The use of spinal manipulative therapy for pediatric health conditions: a systematic review of the literature. *J Can Chiropr Assoc.* 2012;56(2):128-41.
11. Harlor AD, Bower C. Hearing assessment in infants and children: recommendations beyond neonatal screening. *Pediatrics.* 2009 Oct;124(4):1252-63.
12. Kutz JW, Meyers AD. Medscape. Audiology pure-tone testing [Internet]. 2016 [cited 2016 Sep 11]. Available from: <http://emedicine.medscape.com/article/1822962-overview>
13. Lopes MA. Spinal examination. In: Plaughner G, editor. *Textbook of clinical chiropractic: a specific biomechanical approach.* Baltimore: Williams & Wilkins; 1993:73-109.
14. McCoy M. Paraspinal thermography in the analysis and management of vertebral subluxation: a review of the literature. *A Vertebral Subluxation Res.* 2011 Jul;57-66.
15. Berg B. Resolution of fatigue, malaise & depression in a 30 year old male following subluxation-based chiropractic care utilizing Gonstead technique: a case study. *A Vertebral Subluxation Res.* 2016 Feb;10-20.
16. Herbst RW. *Gonstead chiropractic science and art.* Mt. Horeb: Sci-Chi Publications, 1968.
17. Electronic Development Labs, Inc. (US). *The Nervo-Scope® ETS Series* [Internet]. Danville (VA): Electronic Development Labs, Inc. 2014 [cited 2016 Sep 10]. Available from: <http://www.nervo-scope.com>
18. Bonnin E. Electronic development labs, inc. warning letter [Internet]. U.S. Food and Drug Administration. 2014 [cited 2016 Sep 11]. Available from: <http://www.fda.gov/ICECI/EnforcementActions/WarningLetters/2014/ucm421355.htm>
19. Young RB. Electronic development labs, inc. close out letter [Internet]. U.S. Food and Drug Administration. 2015 [cited 2016 Sep 11]. Available from: <http://www.fda.gov/ICECI/EnforcementActions/WarningLetters/2015/ucm452092.htm>
20. Plaughner G. Lower cervical spine. In: Plaughner G, editor. *Textbook of clinical chiropractic: a specific biomechanical approach.* Baltimore: Williams & Wilkins; 1993:279-302.
21. Araghi JH. Upper cervical spine. In: Plaughner G, editor. *Textbook of clinical chiropractic: a specific biomechanical approach.* Baltimore: Williams & Wilkins; 1993:303-24.
22. Ferrance RJ, Miller J. Chiropractic diagnosis and management of non-musculoskeletal conditions in children and adolescents. *Chiropr & Osteopat.* 2010;18(14):1-8.
23. Brown CD. Improved hearing and resolution of otitis media with effusion following chiropractic care to reduce vertebral subluxation. *J Pediatr Matern & Fam Health-Chiropr.* 2009 Mar; 1-7.
24. Cuthbert SC, Rosner AL. Applied kinesiology management of candidiasis and chronic ear infections: a case history. *J Pediatr Matern & Fam Health- Chiropr.* 2010 Aug;122-9.
25. Dwyer P, Boysen J. Resolution of conductive hearing loss due to otitis media after chiropractic treatment. *J Clin Chiropr Pediatr.* 2011 Dec;12(2):903-9.
26. Fedorchuk C, Cohen A. Resolution of chronic otitis media, neck pain, headaches & sinus infection in a child following an increase in cervical curvature & reduction of vertebral subluxation. *J Pediatr Matern & Fam Health-Chiropr.* 2009 Jun;1-8.
27. Feranti M, Alcantara J, Brinkley C. Chronic otitis media, failed tympanostomy tube surgery & resolution following adjustment of vertebral subluxation. *J Pediatr Matern & Fam Health- Chiropr.* 2016 Jan;5-8.
28. Lanjopoulos C, Lanjopoulos D. Resolution of chronic otitis media, difficulty sleeping, and tactile hypersensitivity in a child undergoing subluxation-based chiropractic care. *J Pediatr Matern & Fam Health-Chiropr.* 2012 Sep;81-4.
29. Marino FM, Butt A. Chiropractic care of a pediatric patient suffering from a recurrent otitis media and respiratory syncytial virus: a retrospective case report. *J Pediatr Matern & Fam Health- Chiropr.* 2010 Dec;183-6.
30. O'Connor K, Schneider G, Alcantara J. Resolution of otitis media, improvement in hearing & avoidance of myringotomy tubes following chiropractic care in a child: a case report & selective review of the literature. *J Pediatr Matern & Fam Health- Chiropr.* 2014 Jul; 47-54.
31. Pilsner R, Richardson M. Improvements in hearing, speech, development, and behavior following chiropractic in a 4 year old male. *J Pediatr Matern & Fam Health-Chiropr.* 2011 Feb; 14-22.
32. Steinberg B, Doerr A. Resolution of chronic otitis media, constipation & sleep disturbance following adjustment of subluxations in a 2-year-old child: a case study & review of literature. *J Pediatr Matern & Fam Health- Chiropr.* 2016 Jul;75-9.
33. Stone-McCoy P, Boutilier A, Black P. Resolution of otitis media in a nine month old undergoing chiropractic care: a case study and selective review of the literature. *J Pediatr Matern & Fam Health- Chiropr.* 2010 Jun;99-105.
34. Stone-McCoy P, Korn C. Resolution of otitis media & avoidance of tympanostomy tubes in a 16-month old with birth trauma following subluxation based care: a case study and selective review of literature. *J Pediatr Matern & Fam Health- Chiropr.* 2013 May;39-46.
35. Degenhardt BF, Kuchera ML. Osteopathic evaluation and manipulative treatment in reducing the morbidity of otitis media: a pilot study. *J Am Osteopath Assoc.* 2006 Jun;106(6):327-34.
36. Froehle RM. Ear infection: a retrospective study examining improvement from chiropractic care and analyzing for influencing factors. *J Manipulative Physiol Ther.* 1996;19:169-77.
37. Zhang JQ, Snyder BJ. Effect of the Toftness chiropractic adjustments for children with acute otitis media. *J Vert Sublux Res.* 2004 Mar;1-4.
38. Mills MV, Henley CE, Barnes LLB, Carreiro JE, Degenhardt BF. The use of osteopathic manipulative treatment as adjuvant therapy in children with recurrent acute otitis media. *Arch Pediatr Adolesc Med.* 2003 Sep;157:861-6.
39. Steele KM, Carreiro JE, Viola JH, Conte JA, Ridpath LC. Effect of osteopathic manipulative treatment on middle ear effusion following acute otitis media in young children: a pilot study. *J Am Osteopath Assoc.* 2014;114(6):436-47.

40. Wahl RA, Aldous MB, Worden KA, Grant KL. Echinacea purpurea and osteopathic manipulative treatment in children with recurrent otitis media: a randomized controlled trial. *BMC Complement Altern Med.* 2008 Oct;8(56).
41. Lopes MA. Vertebral subluxation complex. In: Plaughner G, editor. *Textbook of clinical chiropractic: a specific biomechanical approach.* Baltimore: Williams & Wilkins; 1993:52-72.
42. Kent C. Models of vertebral subluxation: a review. *J Vert Sublux Res.* 1996 Aug;1(1):1-7
43. Alcantara J, Alcantara J, Alcantara J. Spinal subluxation. In: Anrig CA, Plaughner G, editors. *Pediatric chiropractic.* 2nd ed. Rev. Philadelphia: Lippincott Williams & Williams; 2013.
44. McCoy M, Carrino AJ. Wellness and the chiropractic lifestyle. In: Anrig CA, Plaughner G, editors. *Pediatric chiropractic.* 2nd ed. Rev. Philadelphia: Lippincott Williams & Williams; 2013.
45. Bronfort G, Haas M, Evans R, Leininger B, Triano J. Effectiveness of manual therapies: the UK evidence report. *Chiropr & Osteopat.* 2010;18(3).

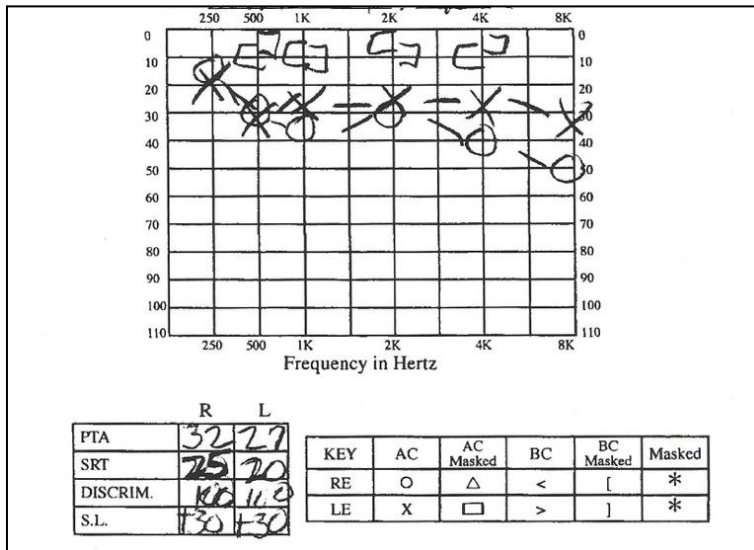
Appendix

Level of Subluxation	Number of times adjusted
L5	18
C1	12
S2	5
S1	3
T3	5
C7	5
T1	3
L1	1
C2	1
T5	1
T6	1
T7	1
T9	1

Table 1. The location and frequency of segments adjusted in the case of a 10-year-old under Gonstead chiropractic care for 1-year duration.

Author	Year	Journal	Type	Technique	Subject Age	Hearing loss
Brown	2009	J Pediatr Matern & Fam Health	Case study	Diversified	3 yrs	yes
Cuthbert & Rosner	2010	J Pediatr Matern & Fam Health	Case study	Applied Kinesiology	6 yrs	no
Degenhardt & Kuchera	2006	J Am Osteopath Assoc	Case series	OMT	7-35 mo	no
Dunn-Sigouin	2015	J Clin Chiropr Pediatr	Case study	Diversified, myofascial release, sinus effleurage	23 mo	no
Dwyer & Boysen	2011	J Clin Chiropr Pediatr	Case study	Gonstead, diversified, SOT, AK craniopathy	6 yrs	yes
Fallon	1997	J Clin Chiropr Pediatr	Case series	Diversified, effleurage of SCMs	6mo-5yrs	no
Fedorchuck & Cohen	2009	J Pediatr Matern & Fam Health	Case study	CBP	8 yrs	no
Feranti et al	2016	J Pediatr Matern & Fam Health	Case study	Diversified with Activator instrument	4 yrs	no
Froehle	1996	J Manipulative Physio Ther	Case series	Diversified with Activator instrument and modified AK	<5 yrs	no
Lanjopoulos & Lanjopoulos	2012	J Pediatr Matern & Fam Health	Case study	Activator Methods	2 yrs	no
Marino & Butt	2010	J Pediatr Matern & Fam Health	Case study	Diversified	21 mo	no
Mills et al.	2003	Arch Pediatr Adolesc Med.	RCT	OMT	6mo-6yrs	yes
O'Connor	2014	J Pediatr Matern & Fam Health	Case study	Diversified	9 yrs	yes
Pilsner & Richardson	2011	J Pediatr Matern & Fam Health	Case study	Diversified with Activator & Arthrostim instruments	4 yrs	yes
Saunders	2004	Clin Chiropr	Case study	Diversified, Activator instrument	3 yrs	yes
Sawyer et al.	1999	J Manipulative Physio Ther	RCT	Chiropractic SMT	6mo-6yrs	no
Steele et al.	2014	J Am Osteopath Assoc	RCT	OMT	6mo-2yrs	no
Steinberg & Doerr	2016	J Pediatr Matern & Fam Health	Case study	MC2 with an Integrator	2 yrs	no
Stone-McCoy et al.	2010	J Pediatr Matern & Fam Health	Case study	Philips cranial, diversified, Activator instrument	9 mo	no
Stone-McCoy & Korn	2013	J Pediatr Matern & Fam Health	Case study	Diversified, Activator instrument, Philips cranial, effleurage SCM	16 mo	no
Wahl et al.	2008	BMC Complement Altern Med	RCT	OMT	1-5yrs	no
Zhang & Snyder	2004	J Vert Sublux Res	Case series	Toftness	9 mo-9yrs	no

Table 2. Summary of articles used in discussion of review of literature pertaining to chiropractic and osteopathic manipulative therapy (OMT) in the management of otitis media.



Abbreviation Key¹²
 PTA: pure tone average
 SRT: speech reception threshold
 DISCRIM: word discrimination
 SL: sensation level
 RE: right ear
 LE: left ear
 AC: air conduction
 BC: bone conduction

Figure 1. Audiogram before ventilation tube insertion at 5-years-old showing mild hearing loss of 32 dB and 27 dB in the right and left ears.

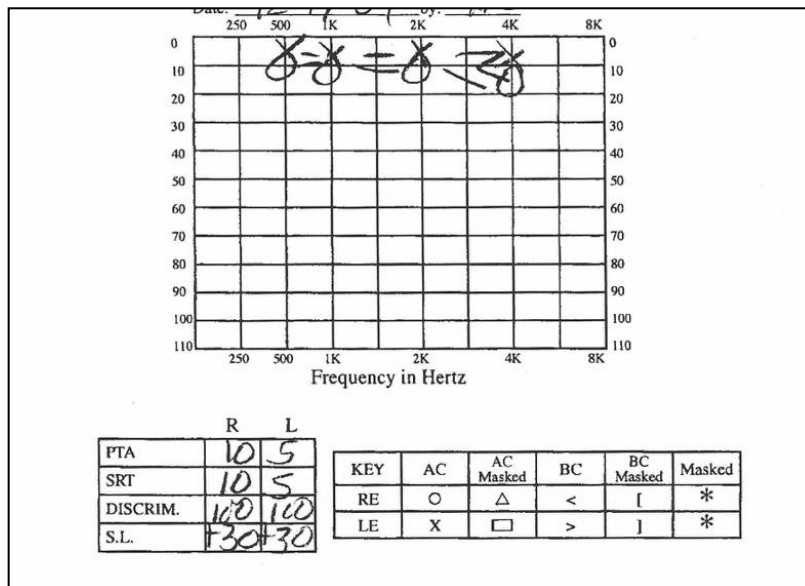


Figure 2. Audiogram after VT insertion at 5-years-old showing restoration of normal hearing.

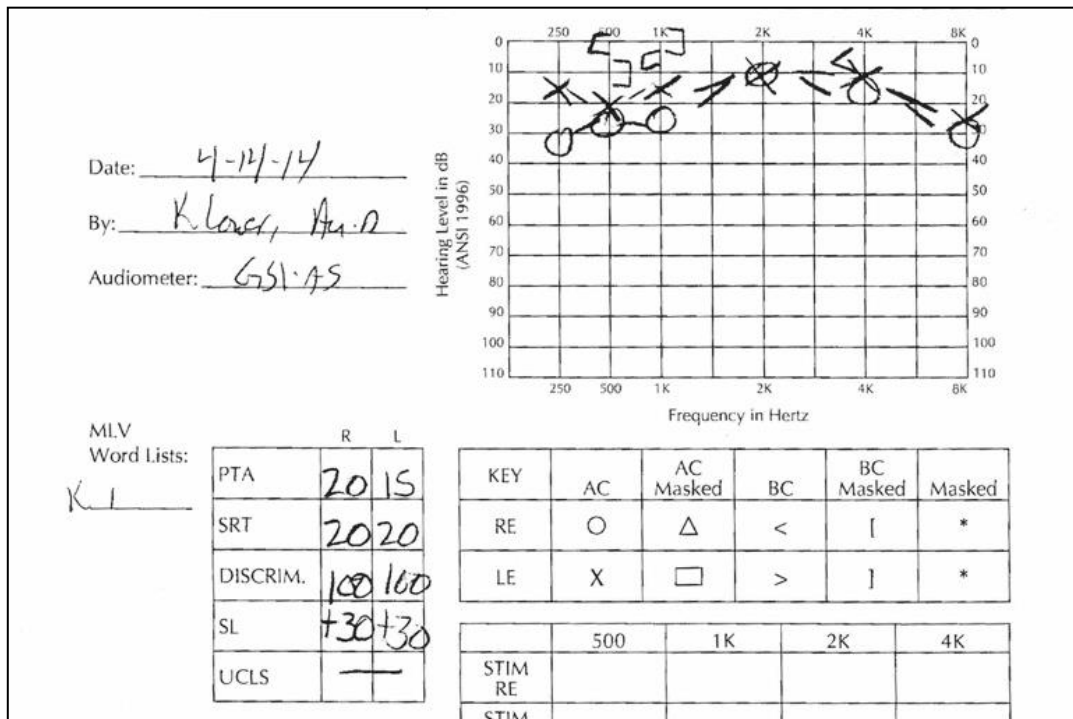


Figure 3. The first audiogram before presenting for chiropractic care at 10-years-old. Abnormal hearing demonstrated.

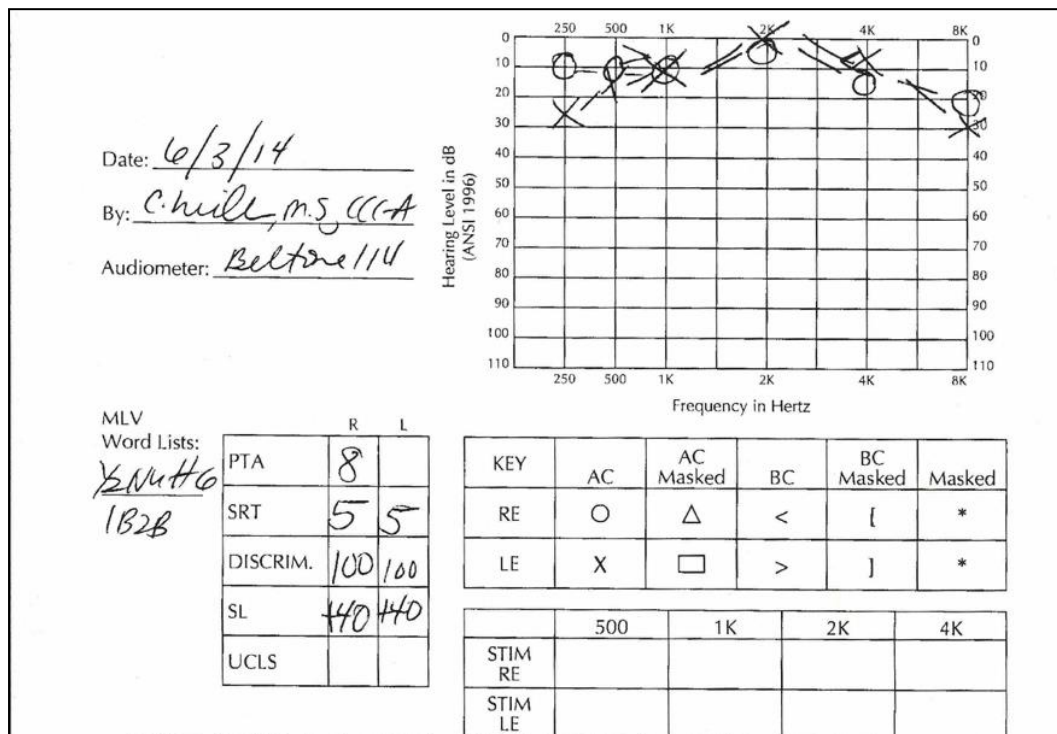


Figure 4. The second audiogram before presenting for chiropractic care at 10-years-old. Normal hearing demonstrated. Measured by a different audiometer than other 2 audiological evaluations.

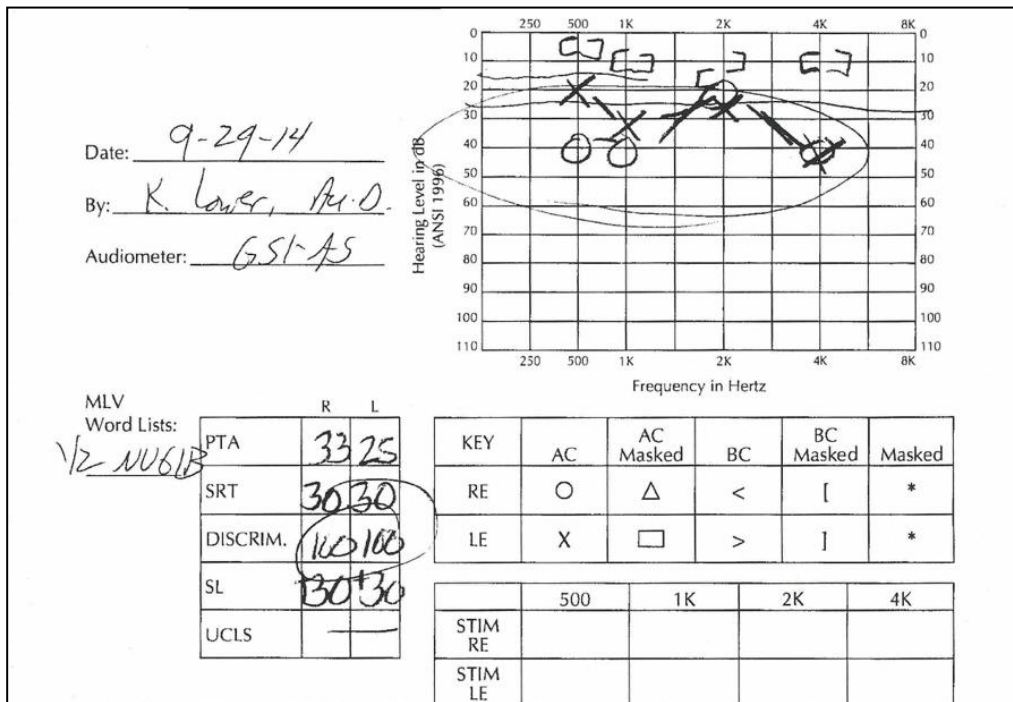


Figure 5: The third audiogram before presenting for chiropractic care at 10-years-old. Abnormal hearing demonstrated.

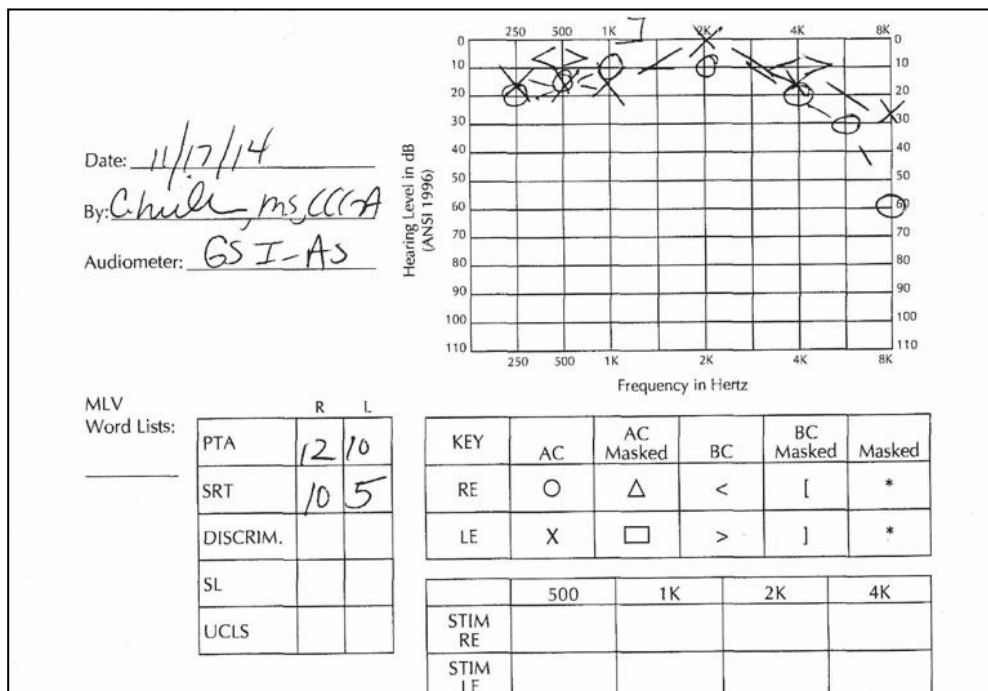


Figure 6. Audiogram following chiropractic treatment showing normal hearing after the 6th visit.

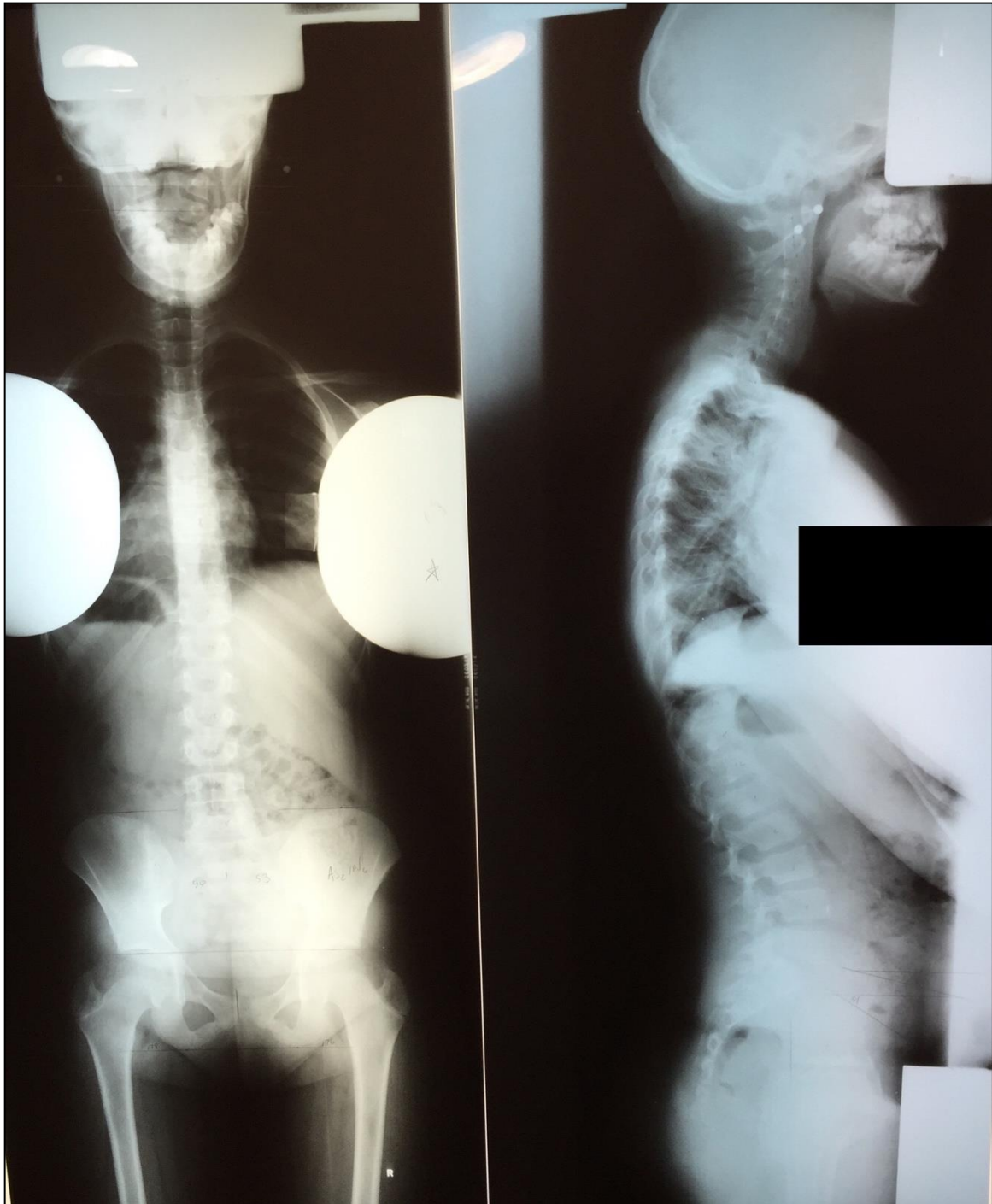


Fig 7: 14x36 Full spine AP and lateral radiographic projections of the 10-year-old Pertinent listings demonstrated on these films: right ilium AS₂In₆; L5 PL; Atlas ASR.